April 19, 2023



PALM BEACH GARDENS
MEDICAL CENTER
PALM BEACH HEALTH NETWORK

Palm Beach Gardens Medical Center

Teresa C. Urquhart, Chief Executive Officer

PALM BEACH GARDENS
MEDICAL CENTER
PALM BEACH HEALTH NETWORK

Main Building Façade



+

- OR Room 5
- 3 West Cardiac/Telemetry Unit
- Emergency Department Renovations

PALM BEACH GARDENS
MEDICAL CENTER
PALM BEACH HEALTH NETWORK

Medical Office Building Façade

+

- MOB Common Areas

PALM BEACH GARDENS
MEDICAL CENTER
PALM BEACH HEALTH NETWORK

Timothy Burke, MD, FAANS

Board-Certified Neurosurgeon

Education:

- Completed his Internship and Residency at George Washington University School of Medicine and Health Sciences

Specializes in:

- Cranial Base Surgery
- Stereotactic Surgery
- Neuro-Oncology

Holds Membership in:

- American Association of Neurological Surgeons
- Congress of Neurological Surgeons

Technological Advances in Neurosurgery:

Timothy G. Burke, MD

PALM BEACH GARDENS
MEDICAL CENTER
PALM BEACH HEALTH NETWORK

Neurosurgery History

- Earliest Neurosurgery attributed to Incas
  - Some believe they were able to achieve high survival rates
    - Avoided dangerous regions
    - Safe surgical techniques
    - Use of herbs and balms for analgesia and antibacterial activity
- Likely the Neurosurgery(trephination) was widely spread
  - China- Hua Tuo (up to 10,000BC)
  - Egypt
  - Oceana(clear evidence on skulls)
  - Arabia- Avicenna and Rhazes
- Moderna era
  - Harvey Cushing-expanded exposure of craniotomy
  - Horsley
  - Krause







What to operate on and how to get there

- Locating tumors/pathology based upon clinical knowledge from previous cases
  - Wilder Penfield
  - Father of electrical stimulation

Homunculus

- Distorted representation of human body
- Based upon volume of brain dedicated to specific sensory and motor functions

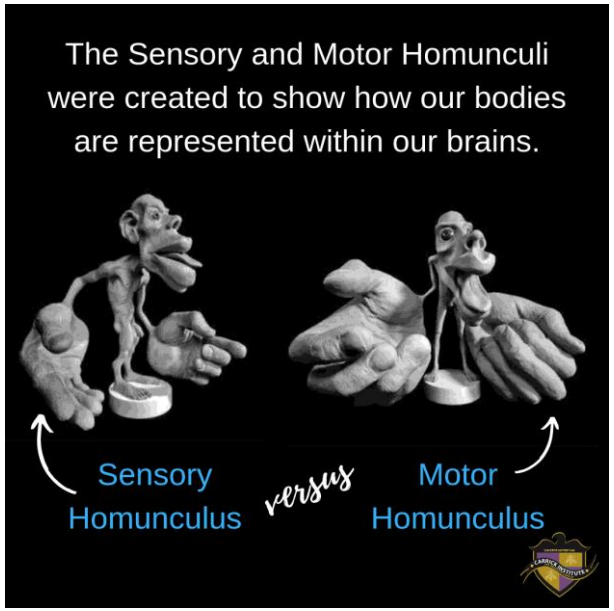

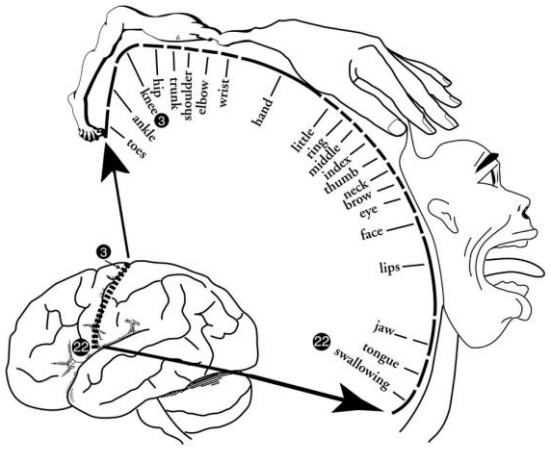

The Dark Ages

- No imaging
  - Pneumoencephalogram
  - CT
  - MRI
  - PET
- Light
  - Headlights
  - Microscopes
  - Endoscopes
  - Exoscopes

The Modern World

- Pre-op imaging
  - Detailed anatomy
  - Ability to see fibers(tracts and connections
- Image guided surgery
  - GPS in the OR
- Digitally augmented microscopy
  - Visible light
  - Use of Fluorophores

Preopeative Imaging

- MRI
  - Detailed anatomical assessment of neural structures
    - Gray matter
    - White mater
    - Blood vessels
  - Tract visualization requires 3D rendering of white matter over great distances

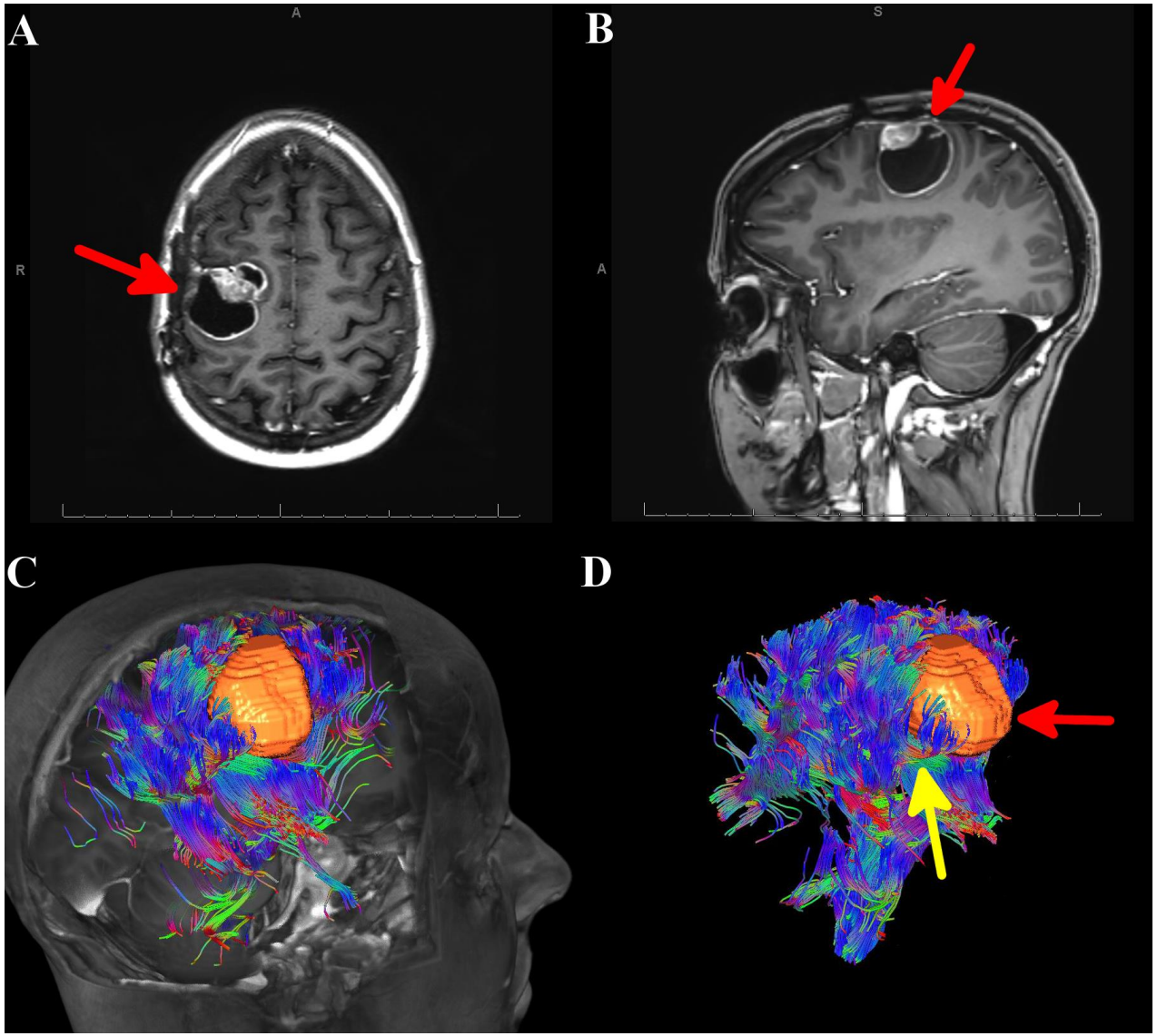

Tractography

- Utilizes Brownian movement of water on MRI
- Measures the relative magnitude of diffusion of H2O
- We can now see:
  - Corticospinal tracts
  - Visual pathways
  - Sensory tracts

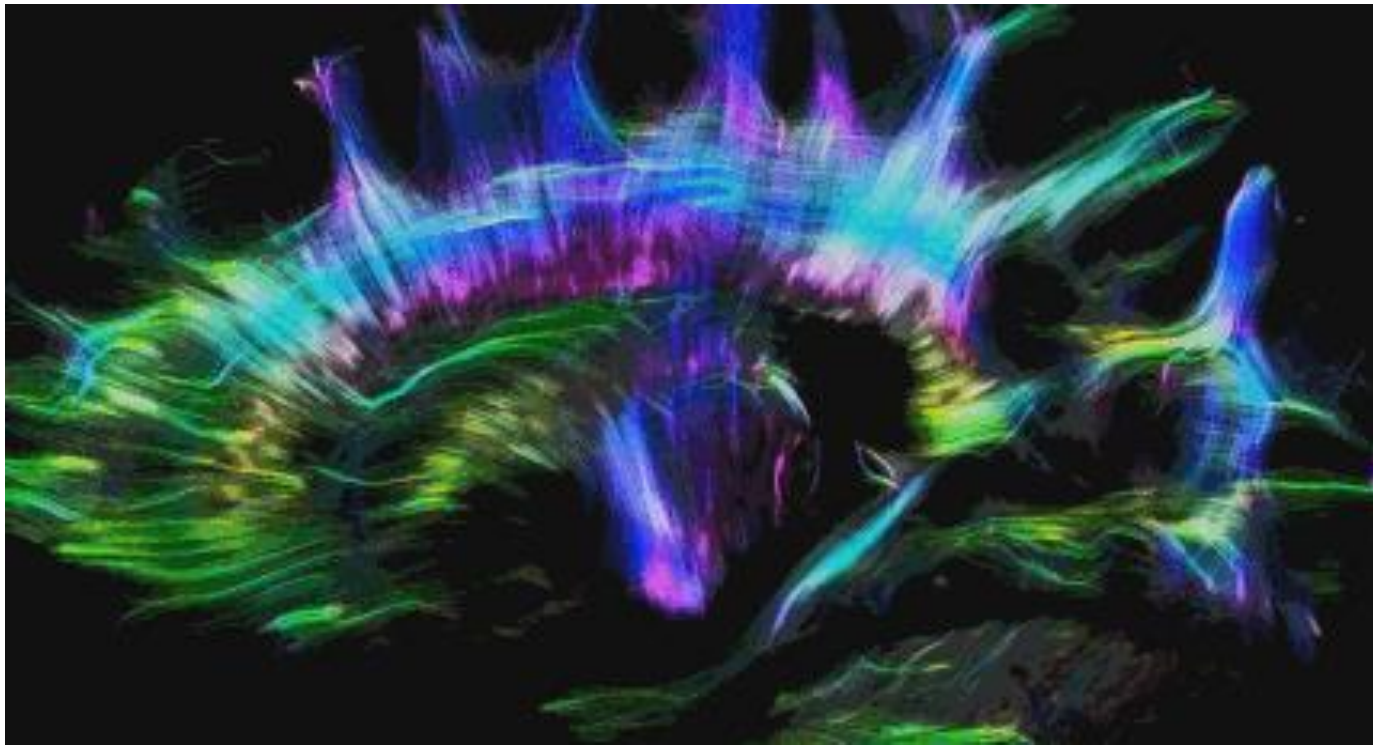

Stereotactic Navigation

- Originally developed from frame based systems for (Horsley/Clarke)
  - Biopsy
  - Stereotactic radiation
  - Placement of electrodes
- Targeting is taken from:
  - X-Y-Z axis
- Limited to single point/target localization



Frameless Stereotaxy

- Image based
- Utilizes infrared light
- Volumetric calculation from CT/MRI
  - Allows continuous image display
    - X-Y-Z axis

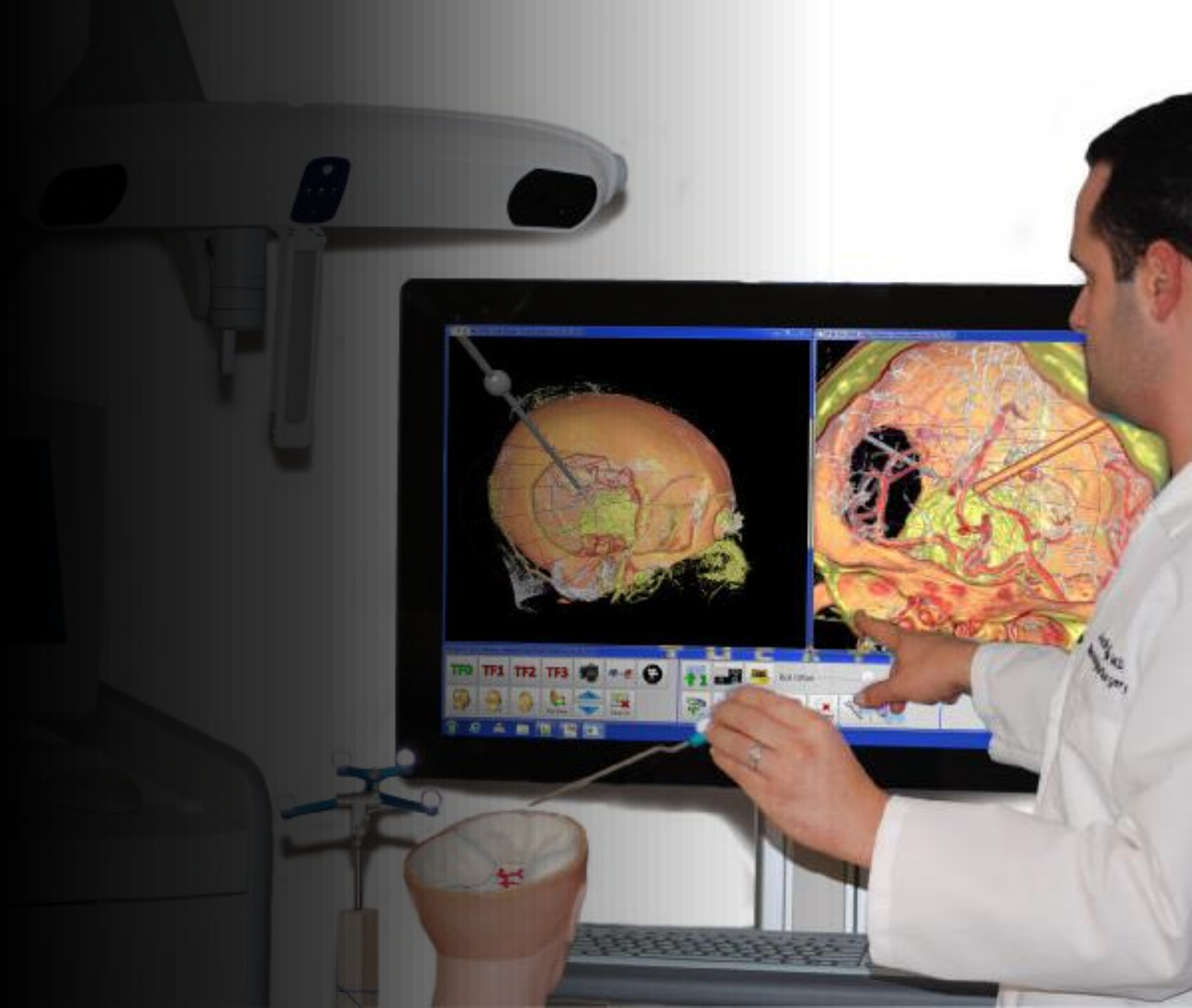

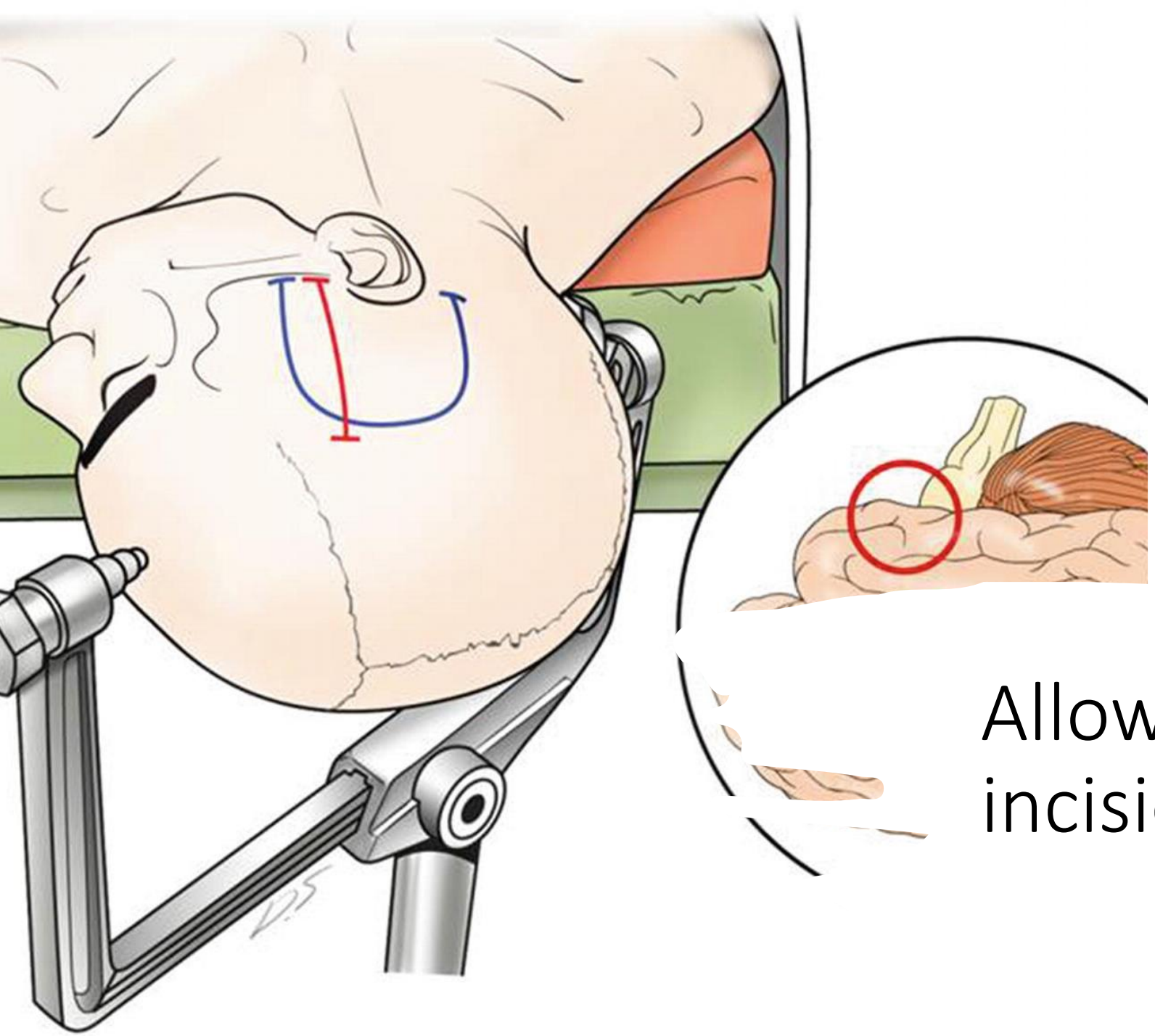

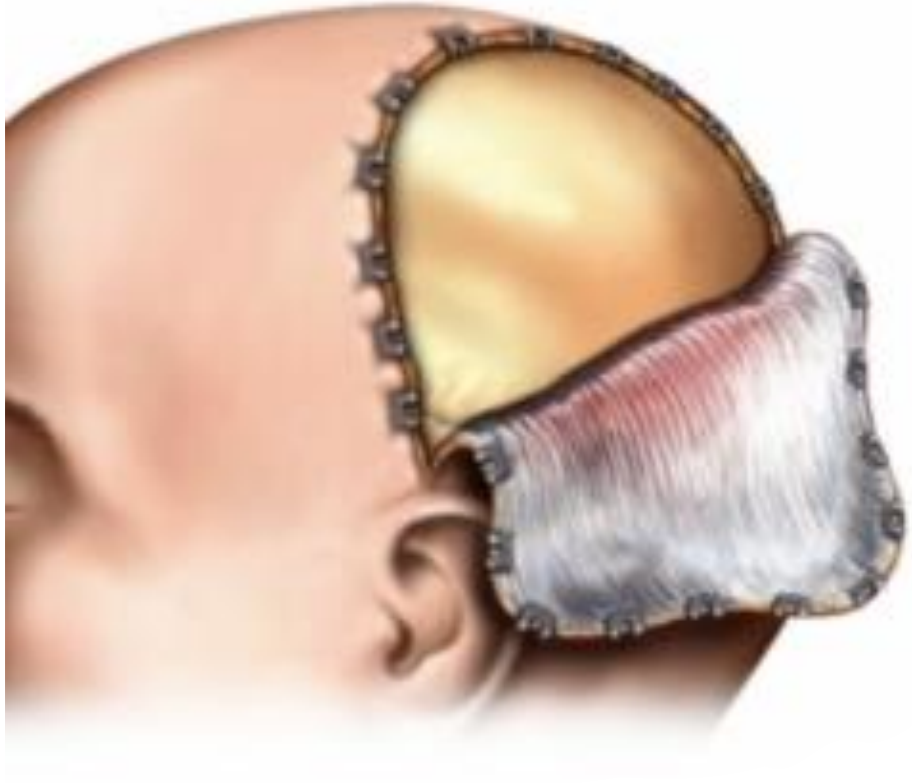

Allows safe tailoring of incisions

Targeted Craniotomy

- Small skin incision
- Small tailored craniotomy
- Safely utilize white matter access to deep and superficial regions
  - Utilize tractography
  - Self protecting operative sheaths/ports
- Digitally enhanced visual information:
  - Visible light
  - Fluorphores
  - Targeted molecules

Retraction Injury

- Challenges of subcortical surgery being with retraction injury
  - Dispersion of Pressure on Tissue
  - Tissue “creep”
  - Visualization at Depth

Flat Blade Retractors → Endoscopy → Radial Retractors

BrainPath & VBAS

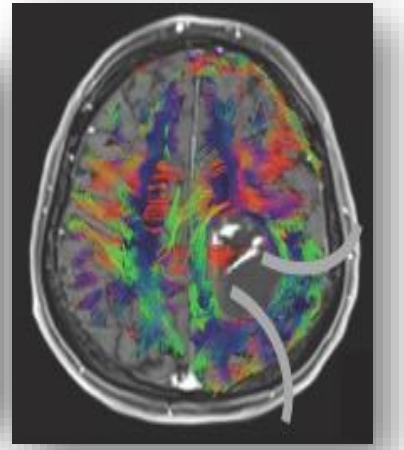

The quiet revolution: retractorless surgery for complex vascular and skull base lesions

Clinical article

ROBERT F. SPETZLER, M.D., AND NADER SANAI, M.D.

Division of Neurological Surgery, Barrow Neurological Institute, St. Joseph's Hospital and Medical Center, Phoenix, Arizona

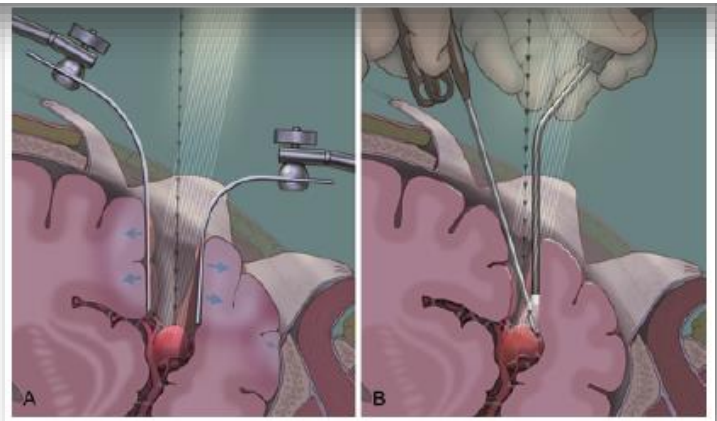

Image Interpretation & Trajectory Planning

Intraoperative Navigation

Access & Cannulation

Optics

Resection

Improved Therapeutics & Delivery

Evolution of Access: BrainPath®

- Designed for ACCESS to allow:
  - Smaller craniotomy
    - ≅30mm or smaller
  - Smaller dural opening
    - ≅ Size of sheath used
    - 13.5mm or 11mm
  - Real-time navigation
  - Gentle dilation of sulcal opening
  - Venting of ICP to be dissipated during cannulation
  - Air-medium & bimanual microsurgical technique

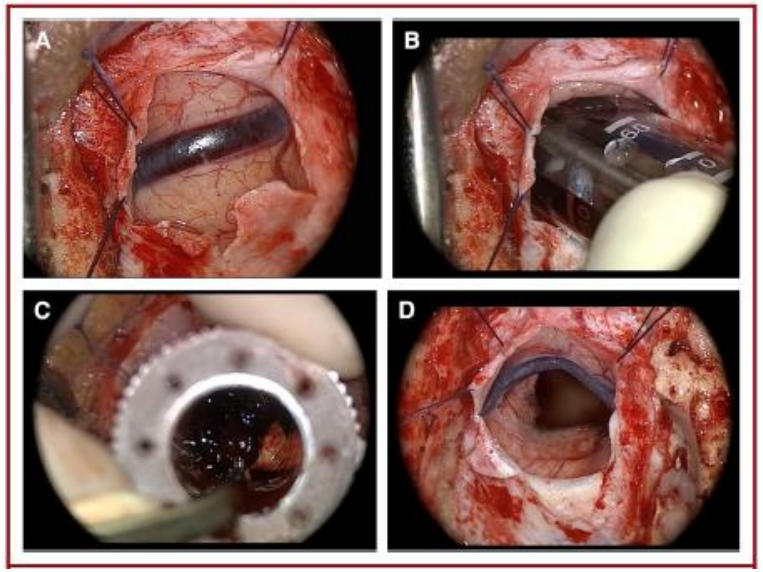

Radial Retraction vs. Access System

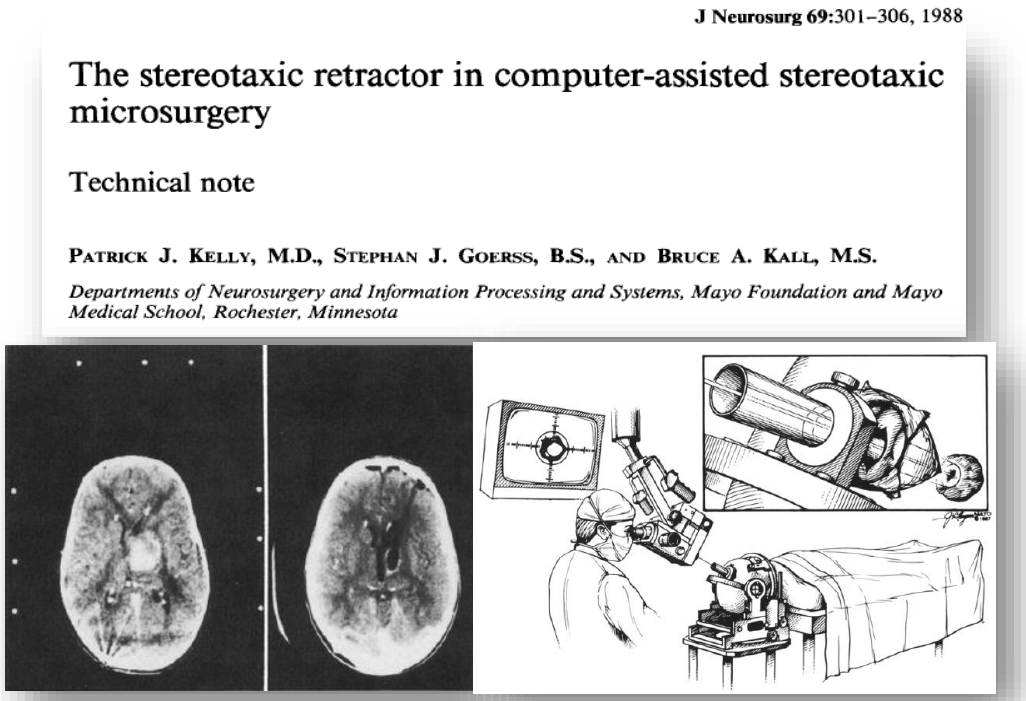

J Neurosurg 69:301–306, 1988

The stereotaxic retractor in computer-assisted stereotaxic microsurgery

Technical note

PATRICK J. KELLY, M.D., STEPHAN J. GOERSS, B.S., AND BRUCE A. KALL, M.S.

Departments of Neurosurgery and Information Processing and Systems, Mayo Foundation and Mayo Medical School, Rochester, Minnesota

- Dr. Pat Kelly (1980s)
- No inclusion of WMT analysis
- Manual Dissection → Placement of Radial Retractor
- SHOWED POTENTIAL FOR LESS INJURY

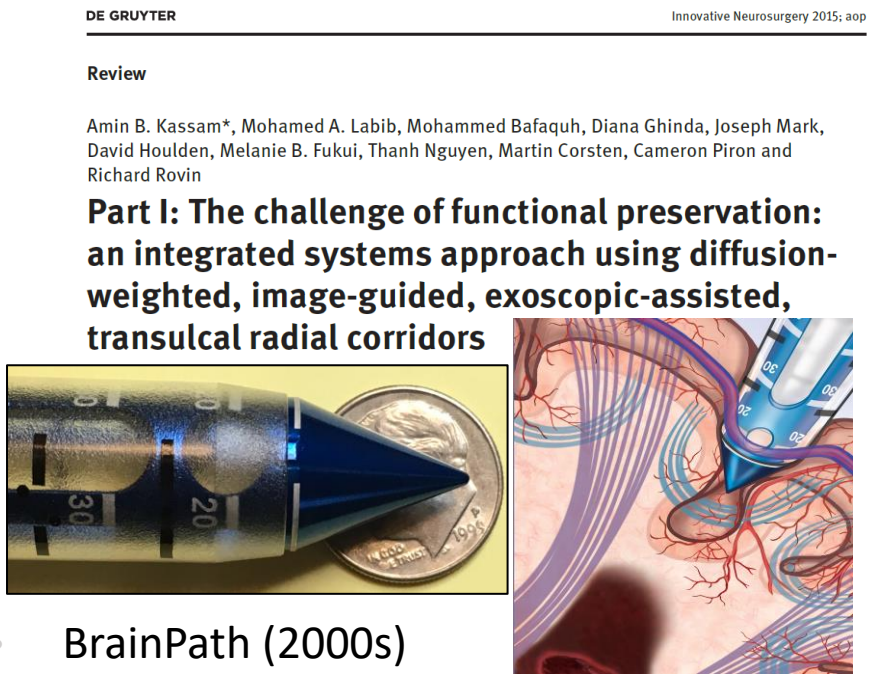

DE GRUYTER Innovative Neurosurgery 2015; aop

Review

Amin B. Kassam*, Mohamed A. Labib, Mohammed Bafaquh, Diana Ghinda, Joseph Mark, David Houlden, Melanie B. Fukui, Thanh Nguyen, Martin Corsten, Cameron Piron and Richard Rovin

Part I: The challenge of functional preservation: an integrated systems approach using diffusion-weighted, image-guided, exoscopic-assisted, transulcal radial corridors

- BrainPath (2000s)
- Considers WMT analysis
- Designed for serial dilation of tissue
- Designed for transsulcal, parafascicular application
- SHOWING POTENTIAL FOR LESS INJURY

Image Interpretation & Trajectory Planning

Intraoperative Navigation

Access & Cannulation

Optics

Resection

Improved Therapeutics & Delivery

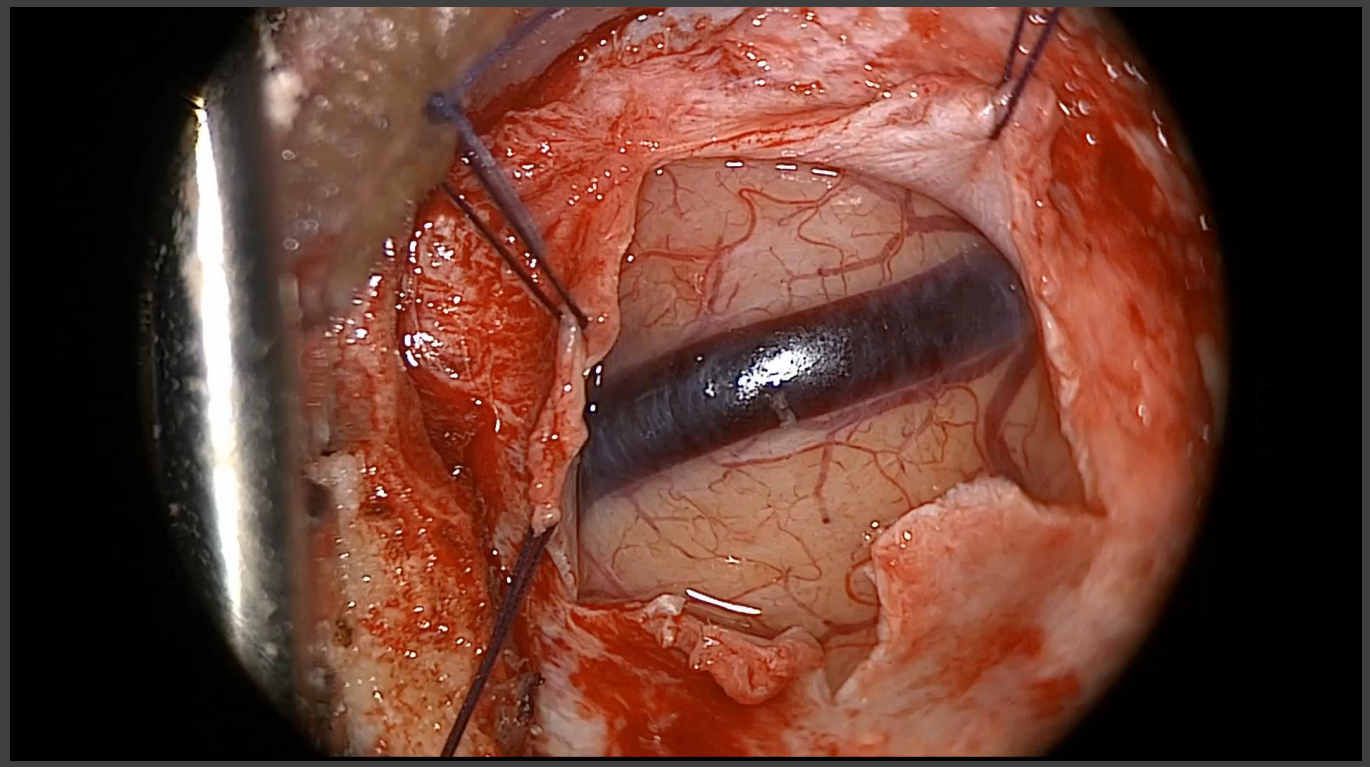

MIPS

Fluorescence Surgery

- Na Fluorescein
  - First used in 1948 for intracranial tumors (Moore et al)
  - Tendency to accumulate where the blood-brain barrier(BBB) is disrupted
  - High dose is visible to naked eye
  - Low dose is visualized by 560nm filter
  - Sensitive
  - Non specific
    - Benign tumors
    - Malignant tumors
    - Radiation necrosis

Fluorescent Surgery

- 5-ALA
  - Converted by certain tumors into protoporphyrin-9
  - FDA approved for grade III and IV gliomas(2017)
  - Excitation at 380-440nm
  - Emission at 620-640nm
  - Sensitive
  - Specific
    - Will not fluoresce radiation changes
  - Expensive
  - Can cause photosensitivity

Figure 2. Kaplan–Meier curves of our results. 5-ALA-GS, 5-aminolevulinic acid-guided surgery.

Mirza et al.

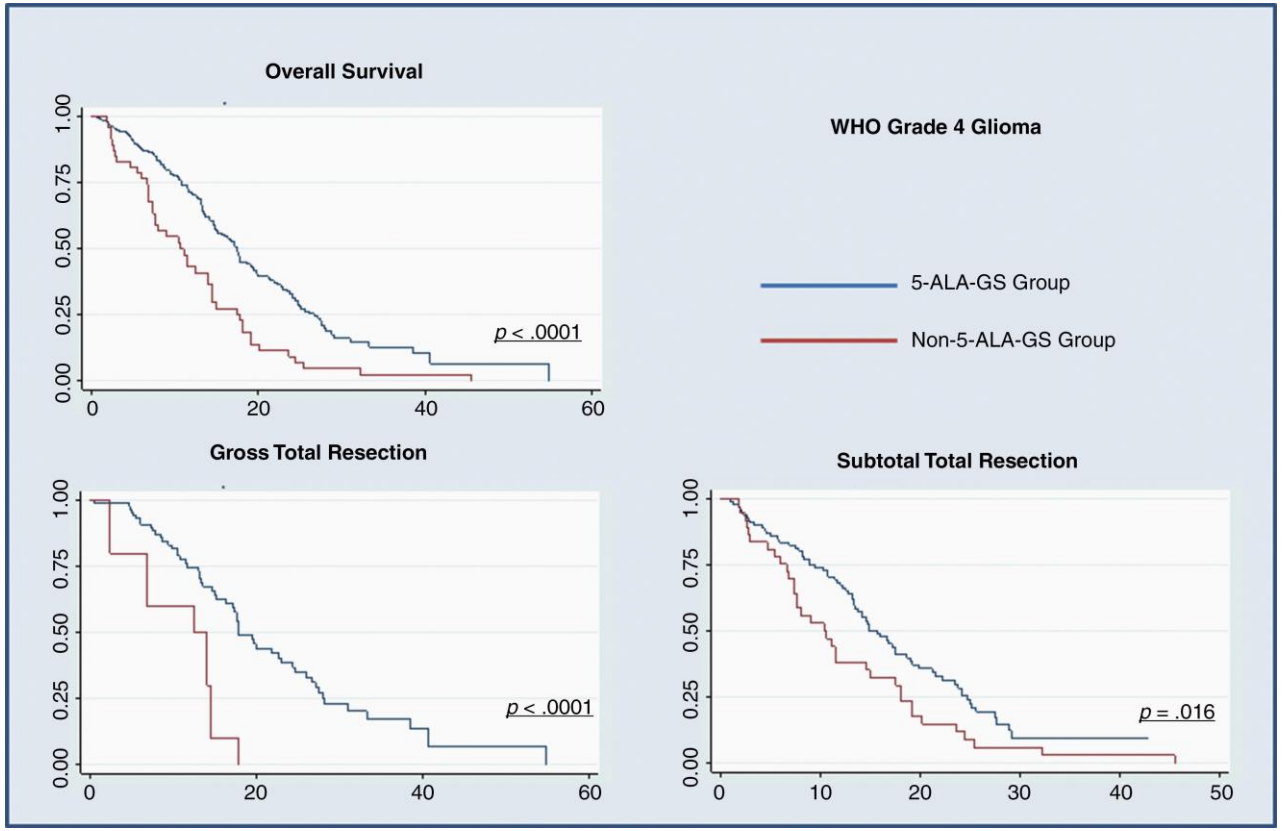

Neuro Oncol Adv, Volume 3, Issue 1, January-December 2021, vdab047, https://doi.org/10.1093/noajnl/vdab047

5-ALA Resection of Glioblastoma

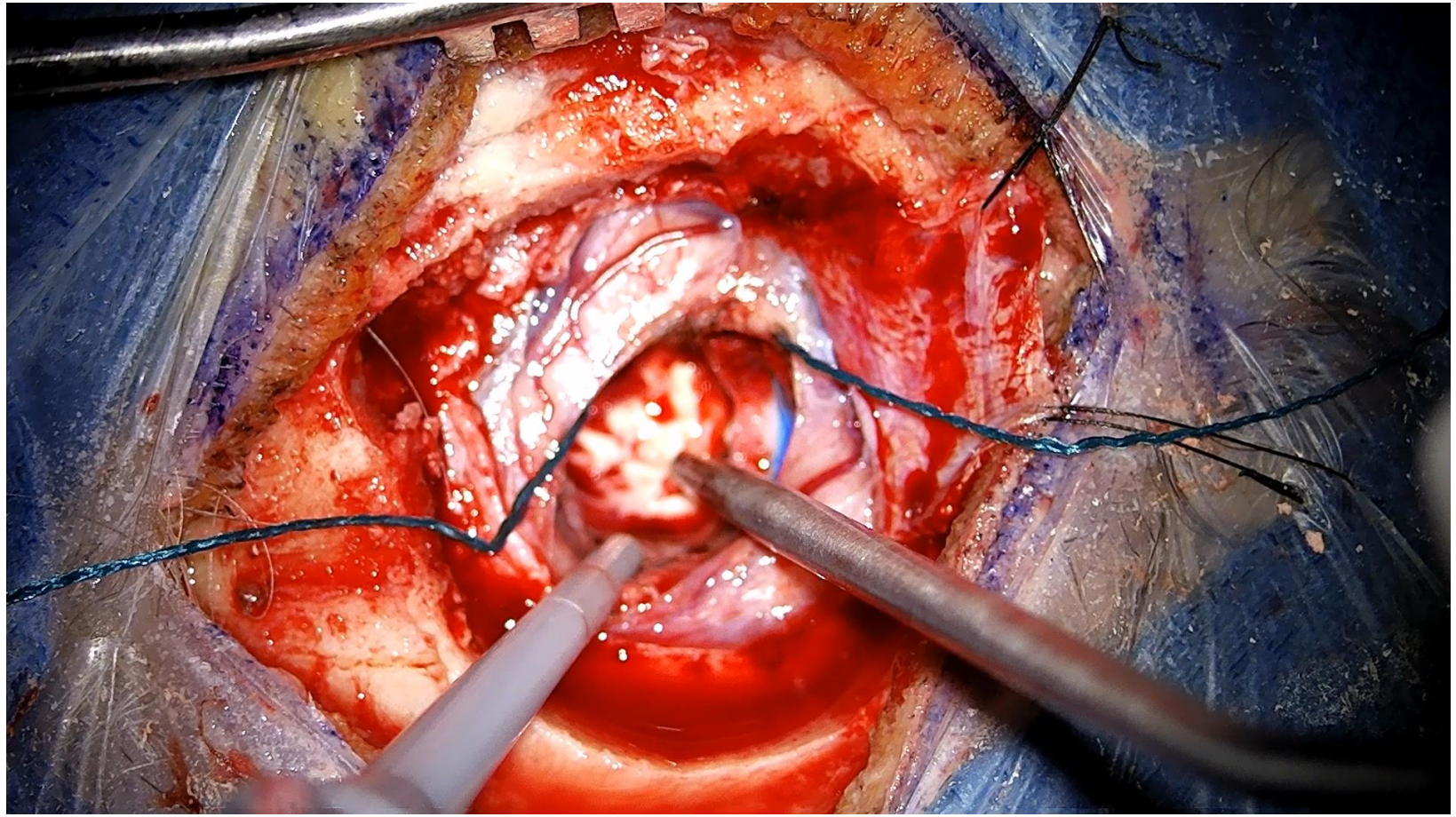

The Future

- Currently 39 Fluorescent agents in clinical trials
  - clinicaltrials.gov
- Targeted molecules
  - Allow for photo therapy intra-op
- AI algorithms for determining neural networks
  - Will allow resection approaches to reduce post-op deficits

THANK YOU


PALM BEACH GARDENS
MEDICAL CENTER
PALM BEACH HEALTH NETWORK
PALM BEACH GARDENS MEDICAL
OUTPATIENT ENTRANCE